

Slide 1

Asymmetric Retinitis Pigmentosa

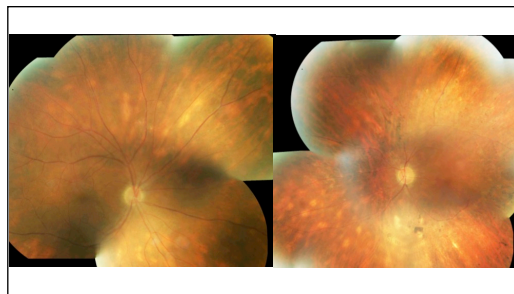
Slide 2

71 year old man referred by his ophthalmologist with 6 year history of RP; maternal aunt had RP; the ophthalmologist wondered "Why the asymmetry?"

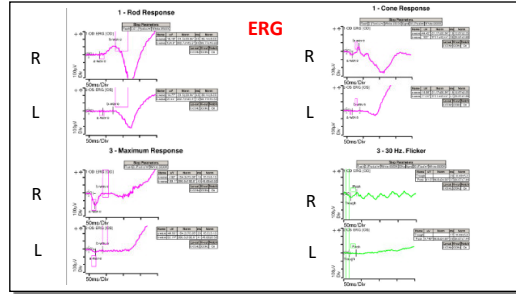
1/1/2016

- VA R- 20/20, L-20/30
- IOP 16 OU
- Pupils – no RAPD
- Slit lamp – 2+ NS and trace vitreous cells OU
- Fundus – as shown

Slide 3



Slide 7



Slide 8

What would you tell the referring ophthalmologist?

Slide 9

What I told the ophthalmologist


- This is not RP
- This is most likely birdshot retinochoroidopathy with asymmetric secondary retinal degeneration
- HLA- A29 was drawn – positive
- Referred to uveitis specialist who placed him on methotrexate 20 mg/week with folate supplementation

Slide 10

32 month follow-up

- Had bilateral ce/iol
- Still 20/20 OU
- Never had CME or vasculitis

Slide 11



Slide 12

2/24/2016 1/10/2019

diagnosis

Patient: CHANDLER RONALD D. DOB: 06-02-1944, Hospital # 3013241, Male, Referring Doctor: SANDRA BROWN, MD
DUB
Exam Inver: Anige Medigan COT OSA Date Tested: 02-24-2016 (Updated: 02/20/19) Time Tested: 10:48:54 AM, Pupils (mm): 6.8
Jaque ID: 8962558-4077-4C8D-8C8C-BE9B-D37C-607A

IMPEDENCE BELOW 5K OULAND AD BETWEEN OPERATION.
2 - Cone Response

B wave amp 117 microvolts B wave amp 51 microvolts

Slide 13

What would you advise the patient?

Slide 14

My advice

- Consider fluocinolone intravitreal implant
 - Retisert 0.59 mg
 - Yutiq 0.18 mg
- Consider increasing systemic immunosuppression
 - Mycophenolate mofetil
 - Cyclosporine A
 - Azathioprine
- The patient refused fluocinolone, either dosage, and will consider adding to systemic immunosuppressive therapy

Slide 15

Birdshot Masquerading as Retinitis Pigmentosa
Several previous cases have been reported

ACTA OPHTHALMOLOGICA 70 (1992) 983-987

CASE REPORT

Birdshot retinochoroidopathy in monozygotic twins

Marianne Fich and Thomas Rosenberg
The National Eye Clinic for the Visually Impaired, Copenhagen, Denmark
