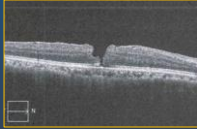


Case 2

1

Macular Hole in Only Eye / Fellow left eye – prosthesis after trauma

- 57 yo male
- HPI: Increased distortion, right eye
- PMH: Retinal tears, lattice s/p laser, ERM , glaucoma
- CE PC IOL OD (4/13) mild edema resolved on medical therapy
- New distortion (6/15)
- Early Full thickness macular hole (6/15)
- VA 20/30





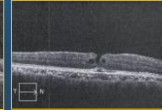
2

Management Options

- Observation
- Surgery in only eye – difficult – store owner, different island than surgical facility, only eye and lives alone
- Other treatment options??


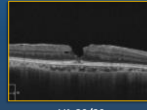
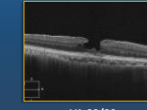
3

Resolved Early Stage Macular Hole After Treatment of CME

<p>Baseline (7/15) Stage IIa Full thickness macular hole</p>  <p>VA 20/30 Significant edema</p> <p>Started prednisolone bid, nepafenac qd Previously on timolol and brimonidine</p>	<p>9/15 Full thickness but pointing edges</p>  <p>VA 20/30</p> <p>Continue on nepafenac qd, prednisolone qd</p>	<p>10/15 Closed hole with paracentral cystic changes</p>  <p>VA 20/25</p> <p>Continuing on bromfenac QD</p>
---	--	--

4

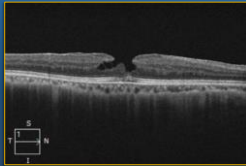
Resolved Early Stage Macular Hole After Treatment of CME

<p>Baseline (7/15) Stage IIa Full thickness macular hole</p>  <p>VA 20/30 Significant edema</p> <p>Started prednisolone bid, nepafenac qd Previously on timolol and brimonidine</p>	<p>1 year later Closure of macular hole</p>  <p>VA 20/20</p> <p>Continue on nepafenac qd, prednisolone qd</p>	<p>2 years later Stable closed macular hole</p>  <p>VA 20/20</p> <p>Continuing on bromfenac QD</p>
--	---	--

5

3 years later

- Stable closed macular hole / lamellar hole configuration
- VA: 20/20
- Chronic daily bromfenac qam to prevent recurrence, timolol bid



6
