

Case 1

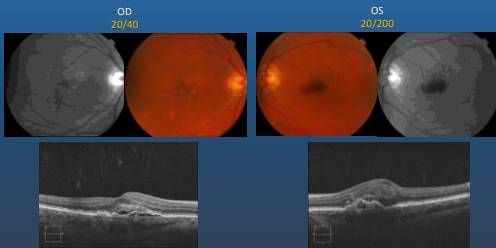
1

72 yo female presents with blurred vision in both eyes (2/2010)

- (OD) 20/40, (OS) 20/200
- 17 mmHg (OU)
- No significant medical or ocular history
- Medication: PreserVision, multivitamins
- Fundus findings:
 - (OD) serous detachment, drusen
 - (OS) serous detachment, subretinal hemorrhage, drusen

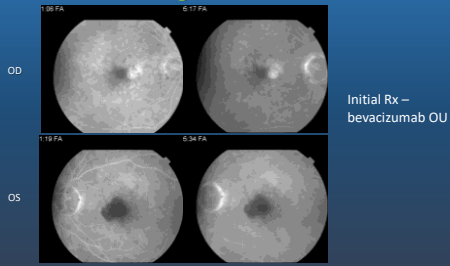
2

Bilateral exudative AMD on presentation



3

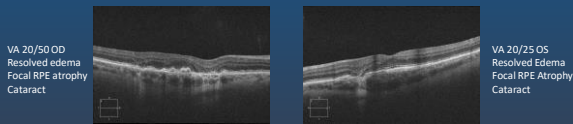
FA – nasal occult leakage OD SR Heme OS



4

Bilateral Exudative Macular Degeneration Receiving Continuous Intravitreal Injections

- Good response to Rx and Extend with recurrences OU
 - S/P 33 ranibizumab injections OU over 4 years
 - Rx and extend to Q 6 weeks
 - Hx recurrent subretinal heme OU

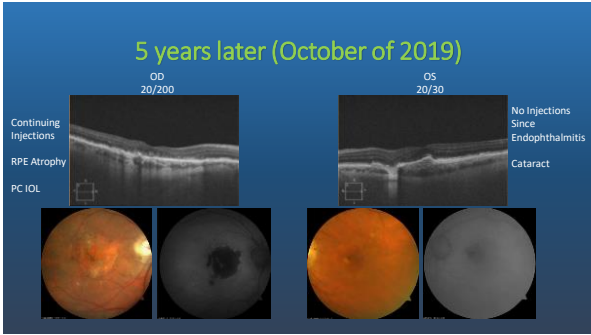


5

Endophthalmitis OS (12/2014)

- Sudden Vision Loss OS
 - Sudden loss of vision to 3/200 1 week later after intravitreal injection
 - 2+ - 3+ vitreous haze without hypopyon
- Vitreous tap, injection of 1 mg vancomycin, 2.25 mg cefazidime, 400 ug dexamethasone
 - Negative vitreous culture
 - Rx with difluprednate Q 2 hours, cyclopentolate, moxifloxacin
- Recovery to 20/30 OS (4/2015)
- Post-endophthalmitis eye OS followed PRN; OD required continuing Rx & Extend

6



7

Unknown Etiology of Involution of CNV after Endophthalmitis

Retin Cases Brief Rep. 2019 Mar 28. doi: 10.1097/ICB.0000000000000866. [Epub ahead of print]

INVOLUTION OF NEOVASCULAR AGE-RELATED MACULAR DEGENERATION AFTER ENDOPTHALMITIS.

Kikame GT^{1,2,3,4,5}, Yamazaki NA⁶, Shandha JP^{2,3,4,7}, Yamane M⁸, Reihan N⁹, Gross J⁹, Ryan EH¹⁰, Flynn HW Jr⁶.

Author Information

- 1 Division of Ophthalmology, Department of Surgery, University of Hawaii School of Medicine, Honolulu, Hawaii.
- 2 The Retina Center at Pali Momi, Aiea, Hawaii.
- 3 Retina Consultants of Hawaii, Aiea, Hawaii.
- 4 Hawaii Macula and Retina Institute, Aiea, Hawaii.
- 5 John A. Burns School of Medicine, University of Hawaii School of Medicine, Honolulu, Hawaii.
- 6 Department of Ophthalmology, Bascom Palmer Eye Institute, University of Miami Miller School of Medicine, Miami, Florida.
- 7 Department of Ophthalmology, University of California San Francisco, Francis I. Proctor Foundation, San Francisco, California.
- 8 Columbia University College of Physicians and Surgeons, New York, New York.
- 9 Carolina Retina Center, Columbia, South Carolina.
- 10 VitreoRetinal Surgery, Minneapolis, Minnesota.

8