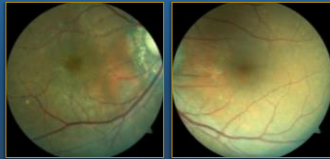


Case 4

1

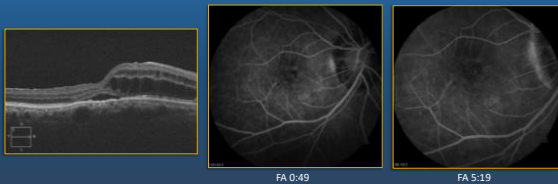
Initial Consult

- Cc: severe blurred central vision OD>OS about 1 year
- VA: 20/400, 20/30
- IOP: 12, 16
- Ocular Hx: NPDR(OU), CEIOL(OU), Dry AMD(OS)
- PMH: diabetes, hypertension, atrial fibrillation
- Medications: pradaxa, digoxin, lisinopril, metformin

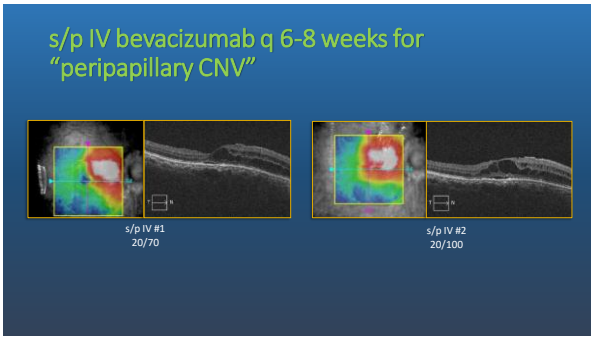


2

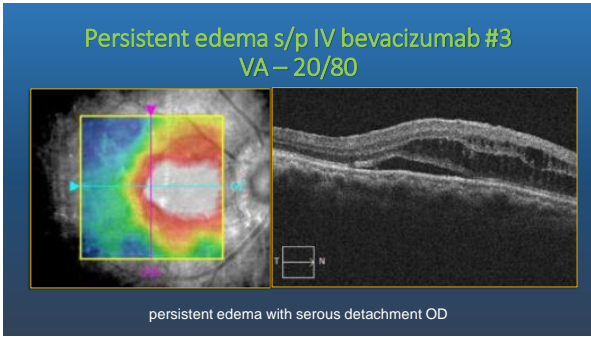
Baseline – Right Eye



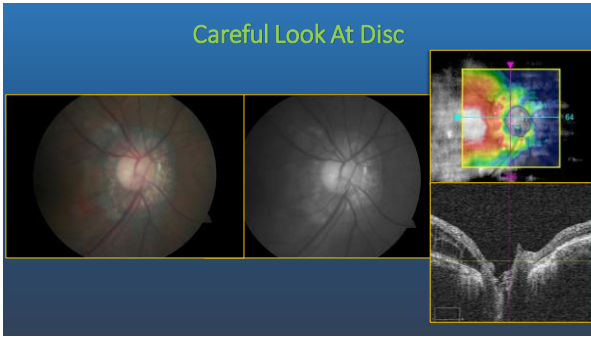
3



4



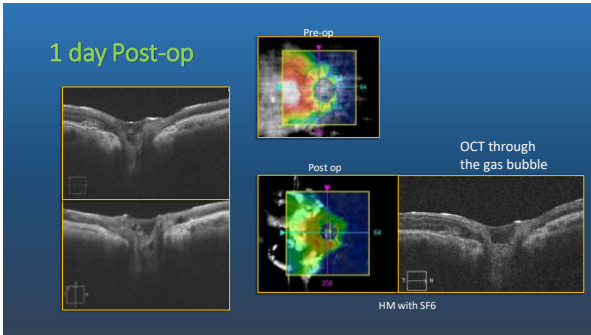
5



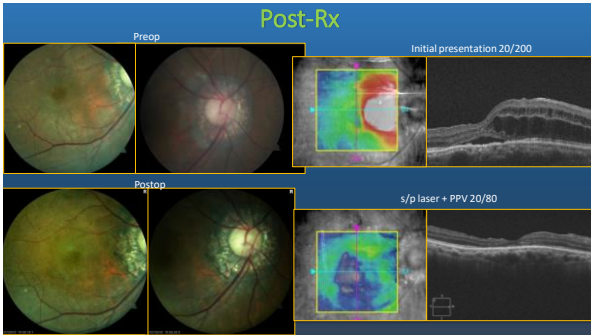
6

- Peripapillary Laser 1 day prior to PPV
- PPV, MP, ILM Peel, GFX (SF6) 1 day later
 - Facedown positioning x 1 week

7



8



9